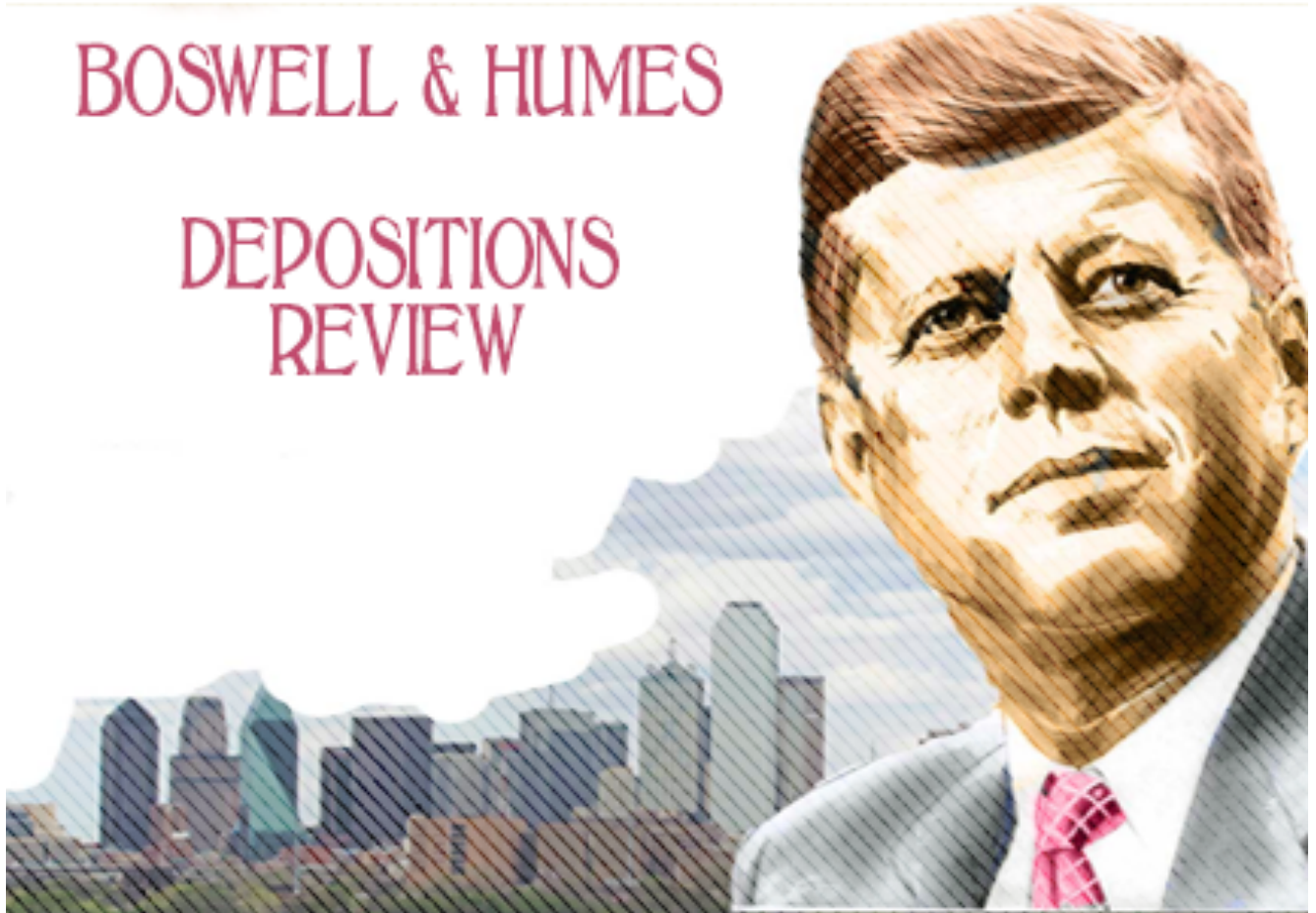

# THE MANTIK VIEW

BOSWELL & HUMES

DEPOSITIONS  
REVIEW



# Deposition of J. Thornton Boswell, M.D., before the AARB on 26 February 1996

---

By David W. Mantik, M.D., Ph.D.

THE MANTIK VIEW

## Appendix F

*[Editor's note: Although he was not a forensic pathologist and had never performed an autopsy on a gunshot victim before, J. Thornton Boswell, M.D., was one of the three medical pathologists who conducted the autopsy on President John Fitzgerald Kennedy. When it became evident that he would be deposed by the 'ARRB, Gary Aguilar, M.D., David W. Mantik, M.D., Ph.D., and others suggested some of the questions that might be asked of him. As it happened 'he was deposed by Jeremy Gunn, who asked many of the questions that Aguilar, Mantik, and others had proposed, with some rather surprising results.]*

*Jeremy Gunn, with Douglas P. Horne in attendance, deposed J. Thornton Boswell, assistant JFK pathologist, on 26 February 1996. The following are excerpts from his deposition. Gunn begins by asking about the throat wound:*

**Gunn:** When you referred to the wound in the anterior neck, what was your first impression?

**Boswell:** ...oh, we thought they had done a tracheotomy, and whether or not that was a bullet wound, we weren't sure, initially. It was after we found the entrance wound \* and then the blood external to the pleura [inside the chest] that we had a track, and that proved to be the exit wound; but it was so distorted by the incision, initially we just assumed it to be a tracheotomy.

*[Mantik note: \* he probably means the back wound]*

**Gunn:** Did you reach the conclusion that there had been a transit wound through the neck during the course of the autopsy itself?

**Boswell:** Oh, yes...

*[Mantik note: This is truly arresting, because it conflicts so grossly with what all the pathologists have said over all these years, but also because the FBI report knows nothing about this. Most conspicuously, this transit wound is not described in the official autopsy report! Boswell here is contradicting the entire story told by the pathologists over many decades. It is impossible to know if these are now his (possibly) honest recollections, and that he has simply forgotten the official cover story. In any case, his statements are totally unexpected.]*

**Gunn (p.44):** ...Do you recall thinking that ...that the anterior neck may have been a wound of some sort?

**Boswell:** I think it was pretty obvious ...that it was a tracheotomy wound. Then, as the evening progressed, the question became whether it was both an exit wound and a

tracheotomy wound, because right in the middle there was what appeared to be the exit wound through which they had cut.

*[Mantik note: Again, this is a striking admission totally at odds with the story that Humes told until his death in 1999, and that the other pathologists supported. Humes always insisted that he knew nothing about a projectile wound in the throat until he spoke to Dr. Perry (who had performed the tracheotomy) on Saturday morning. How Boswell can admit to seeing this projectile wound at the autopsy when it is not mentioned at all in the official autopsy report, only demonstrates his remarkable flexibility of mind.]*

**Gunn** (p. 49): Do you remember whether the fresh brain was weighed?

**Boswell**: I doubt that it was weighed... Well, I shouldn't say that. It was formalin fixed. We floated them in formalin and a piece of cloth, and it was taken, and it probably was weighed. Why the weight is not down here, I do not know.

*[Mantik note: Boswell is here referring to his own autopsy diagram. Humes has admitted that he had one, too, but that he (most likely) burned it. It is quite possible that Humes's (never officially seen) diagram contained the fresh brain weight. The reason that the fresh brain weight was destined for the dustbin becomes obvious in Home's article about the two brains.]*

**Gunn**: Wouldn't it be a fairly important thing to weigh if there were a gunshot wound to the head?

**Boswell**: Especially with some of it missing, that's true... We had a neuropathologist from the AFIP that came over, and we took it out of the formalin after it was fixed a couple of days in fact, on Monday...

*[Mantik note: This date becomes critical in Home's proposal of two separate brain examinations. Boswell's memory here, too, must be wrong. There is no record of any AFIP pathologist ever examining the brain; Richard Davis, the primary candidate from the AFIP has denied this.]*

**Boswell**: But we elected not to cut the brain because the trauma was evident on the surface...

*[Mantik note: this must be the brain in the extant photographs, it does show an obvious track on the surface]*

**Boswell**: ...without having to cut it, and we thought that it might be important to preserve... And we put it back in the formalin, and it was delivered to Admiral Burkley in a bucket. ...And then we never saw it again.

**Gunn**: When was it delivered to Admiral Burkley?

**Boswell**: I believe it was on Monday, but I'm not sure, because we wrote up an addendum to the autopsy, I think on Monday, after we had examined the brain. And I had read the slides on Sunday, so... and I think [**Humes**] took the slides with the brain and the addendum to Admiral Burkley on Monday. But I'm not absolutely sure. I'll rely on Jim's memory for that.

*[Mantik note: This date becomes important in the two-brain scenario.]*

**Gunn**: (p. 90): ...what portions of the scalp were missing when you first began the autopsy?

**Boswell:** Actually, very little... The morticians were able to cover this defect completely by using some sort of plastic to cover the brain cavity, because there wasn't much bone to replace the brain cavity. But they were able to use his scalp to almost completely close the wound.

*[Humes also agrees with this, although he admits that the scalp actually could not be completely closed. Based upon all of the evidence, the scalp was almost all there, but not enough to close it. Therefore, the posterior scalp photographs (since they show entirely intact scalp, contrary to what both pathologists recalled) cannot be authentic.]*

**Gunn:** So it would be fair to say that, although there was a very large piece of skull missing, there was very little scalp missing.

**Boswell:** Right.

**Gunn** (p. 123): Was a [microscopic] section made of the wound of entrance on the neck or back?

**Boswell:** Both.

*[Mantik note: This is yet one more confirmation of the pathologists' knowledge at the autopsy of the bullet wound in the throat. There would be no reason to take tissue from a simple tracheotomy incision. Cyril Wecht (telephone conversation of 4-19-2000) agrees that no forensic pathologist would sample an uncomplicated tracheotomy incision.]*

**Gunn** later quizzes him on the location of the back wound.

**Boswell** (p. 155): Well, it's certainly not as low as T4 [the fourth thoracic vertebra]. I would say at the lowest it might be T2. I would say around T2. [Even this is much too low for the SBT.]

**Gunn** (p. 190): And approximately what percentage of President Kennedy's brain had been destroyed or removed?

**Boswell:** ...Less than a third...

**Gunn:** A third of the 'right hemisphere' or a third of the 'total...'

**Boswell:** A third of the total.

**Gunn** (p. 193): Was it possible to determine the course of the bullet through the skull by an examination of the brain?

**Boswell:** Not 'of the brain. It was a little bit easier by examination of the skull, but the right hemisphere of the brain is just so torn up, and there's no way of determining a track.

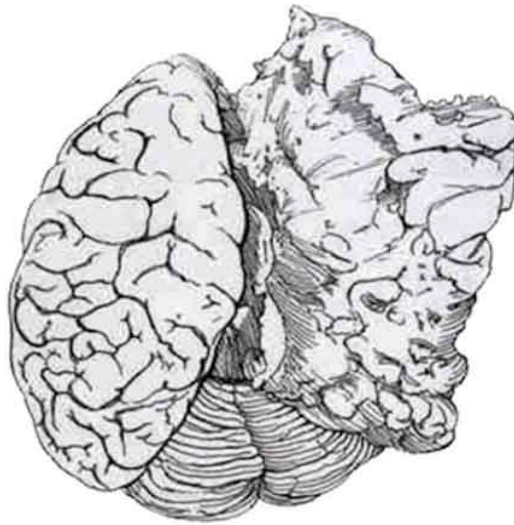


Fig 32-Drawing of Superior Surface of the Brain showing the Extensive lacerations

*Figure 8*

*[Mantik note: The drawings of the brain (Figure 8) suggest a fairly obvious track. At this moment, however, Boswell is recalling the authentic brain. Just about a half page above this Boswell has stated the opposite, namely that the trauma was evident on the surface. He cannot have it both ways. But both were true for him, because he saw two quite different brains at two different dates.]*

Gunn next begins to quiz him on the 6.5 mm object on the frontal X-ray.

**Gunn:** Let me draw your attention to a white semicircular marking in what appears to be in the right orbit. ...Do you know what that object is?

**Boswell:** No.

**Gunn:** Do you know whether that is an artifact... as part... of the developing process or whether that is a missile fragment?

**Boswell:** No, I can't tell you that. I don't remember the interpretation. I see a lot of metallic looking debris, X-ray-opaque material, at the site of the injury.

*[Mantik note: This statement is strange, because this debris is more than 10 cm above the occipital entry site that the pathologists cited for the bullet entry. It is nowhere near the "site of injury" that they described.]*

**Boswell:** And I remember that there were a lot of fragments around the right eye, and the rest of these could be from bullet fragments as well. I'm not sure-we found a couple of very minute metal fragments, but I do not relate them to the X-ray (sic).

*[Mantik note: Boswell has evaded the question that Gunn asked, so Gunn tries again.]*

**Gunn:** Can you relate that, again, apparently large [6.5 mm] object to any of the fragments that you removed?

**Boswell:** No. We did not find one that large. I'm sure of that.

*[Mantik note: With this admission, Boswell confirmed my proposal that this object was not on the frontal X-ray during the autopsy. Neither Humes nor Finck could recall it, either. Quite strikingly,*

*when I asked the autopsy radiologist, Ebersole about it, he abruptly, and forever, stopped the conversation. How likely is it that all three pathologists, the radiologist, and all of the other autopsy personnel, too, could have missed this most important object at the autopsy? I have seen no reasonable answer to this question in the vast assassination literature, and I predict that there will never be one simply because this object was not there. Furthermore, anyone who accepts this conclusion (that it was not there) immediately concurs that there was a post assassination cover-up of considerable magnitude, so that this is extremely hazardous terrain for lone assassin advocates.]*

**Gunn:** (p. 204): Are the minute fragments referenced in the autopsy protocol [the official report] those fragments that go along the top of the [frontal X-ray]?

**Boswell:** Right.

**Gunn:** And I would just note that it says that, "They're aligned corresponding with the line joining the above described small occipital wound [the EOP wound] and the right supraorbital ridge [the bony ridge above the right eye]." To me, it appears as if the line does not correspond with an entrance wound, but would be elsewhere.

*[Mantik note: Now he is telling the truth.]*

**Boswell:** Is that from the autopsy?

**Gunn:** This is the autopsy protocol... But the question for you is: Is what you are seeing on the [lateral] X-ray itself what is being referred to in the portion of the autopsy protocol that I just quoted?

**Boswell:** Right. Although I interpret it differently now...

*[Mantik note: by more than four inches]*

**Boswell:** ...than whoever (sic) did that, I see the line here, but it doesn't connect with the wound of entry, although they (sic) say it does there. And apparently we (sic) gave this to the cops [FBI], O'Neill and Sibert.

**Gunn:** (p. 206): Was there any other X-ray that you now recall having seen that showed a line of metallic fragments connecting to the small wound of entry?

**Boswell:** Not 'of the head.

**Gunn:** Is the fragment trail that you see ...does that correspond to what you saw on the night of the autopsy; as best you recall?

**Boswell:** Yes.

*[Mantik note: So Boswell, like Humes, can offer no explanation for this egregious misrepresentation of the medical evidence, the deliberate displacement of the bullet trail by four inches. This is so gross, in fact, that Boswell has attempted to distance himself from it by saying that "they" did it. He implies it is Humes's fault, yet, at the same time, he claims-again like Humes-that the X-rays are authentic. He cannot have it both ways.]*

**Gunn:** OK. I think that's it for the X-rays.

*After Boswell describes how he was asked to help with the autopsy on Martin Luther King, which he declined to do, Gunn returns to the entry wound at the back of the head.*

**Gunn:** Did you understand or did you ever come to believe that the Clark Panel located the entrance wound at a point superior [at the red spot] to where you had identified the entrance wound in the autopsy protocol?

**Boswell:** I never believed this. I think Jim [**Humes**] at one point came to believe this, because he testified before the House commission (sic) to that effect.

*[Mantik note: I have verified the truth of this statement about Humes; when Humes stood before an enormous blow-up of the lateral skull X-ray before the HSCA, he pointed directly at the higher entry site-the one that the Clark panel, and the HSCA, too, had selected. Wallace Milam gave me a videotape of this interrogation, so I am now certain that, on this sole occasion, Humes really did point at the upper site (near the red spot). Without this videotape, there would have been lingering doubt.]*

*The deposition closes with Boswell drawing, albeit very reluctantly, on a model skull, to illustrate the large hole in the skull. I present and discuss this drawing (as copied by Douglas Horne from the ARRB skull) in the X-ray section of my essay above. It is consistent with the X-rays, and, even more remarkably, it is consistent with the eyewitnesses. It is, however, in gross disagreement with the intact scalp seen on the back of the head (Figure 1). This drawing is an extraordinary and permanent contribution to the entire case, and finally puts many critical issues to bed.*

# Deposition of James J. Humes, M.D., before the AARB on 13 February 1996

Edited by David W. Mantik, M.D., Ph. D

## Appendix G

*[Editor's note: Although he also was not a forensic pathologist and had never performed an autopsy on a gunshot victim before, James J. Humes, M.D., was selected to head the team of three medical pathologists who conducted the autopsy on President John Fitzgerald Kennedy. When it became evident that he would be deposed by the 'ARRB, Gary Aguilar, M.D., David W. Mantik, M.D., Ph. D, and others suggested some of the questions that might be asked of him. As it happened, he was deposed by Jeremy Gunn, whose asked many of the questions that Aguilar, Mantik, and others had proposed, with some rather surprising results. For discussion, see the studies by Aguilar and Mantik elsewhere in this volume.]*

*Chief Pathologist James J. Humes was deposed on 13 February 1996. The 'transcript is 250 pages long, only selected portions are reproduced here. The questioner was Jeremy Gunn, with Douglas P. Home in attendance. The brain is the first topic presented here.*

**Gunn:** (p. 74): Was the fresh brain weighed?

**Humes:** I don't recall. I don't recall. It's as simple as that.

*[Mantik note: FBI agent O'Neill, who took notes at the autopsy, recalls that it was weighed. Boswell, independently, once admitted that he, too, recalled this event (cited elsewhere in this essay). It may have appeared on Humes's notes, which never appeared in any official record.]*

**Gunn:** Would it be standard practice for a gunshot wound in the head to have the brain weighed?

**Humes:** Yeah, we weigh it with a gunshot wound... Normally we weigh the brain when we remove it. I can't recall why, I don't know, one, whether it was weighed or not, or two, why it doesn't show here. I have no explanation for that...

**Gunn:** OK. For the thyroid over on the right column...

**Humes:** There's no weight there... It probably wasn't removed. I don't know. Let me go back for one minute. I was told to find out what killed the man. My focus was on his wounds. I didn't approach it like it was a medical death due to some disease... or whatever. I was focusing primarily and almost exclusively on the wounds. So I don't know. I don't know if I weighed the thyroid or not...

*[Mantik note: a curious comment since JFK was rumored to have had Addison's disease, a diagnosis that might have been determined at the autopsy]*

**Gunn:** And there was a gunshot wound to the neck, wasn't there?

**Humes:** ...There was a bullet wound in the back above the scapula.



*[Mantik note: This is a long distance from the neck, to where Gerald Ford elevated it, without any medical or forensic input.]*

*Gunn next introduces the [woefully inadequate] autopsy diagram, prepared by Boswell. Gunn has just asked about the meaning of the mysterious number 10 on the diagram. [We must remember that Humes's diagram-which he admitted to JAMA that he had made, and Finck's, too (see Slauson's comments on what happened to Finck's in the essay by Gary Aguilar, M.D., elsewhere in this volume), have never been made public. In Boswell's defense, it is possible that one or both of these lost diagrams were more complete and more comprehensible, but were lost because they were not consistent with the single assassin theory.]*

**Humes** (p. 87): ...but your guess is as good as mine, to tell you the truth.

**Gunn:** Up at the top of the skull, there is... I assume 3 centimeters. Do you see that?

**Humes:** Yes.

**Gunn:** Do you have any knowledge about what that would mean?

**Humes:** I certainly don't...

**Gunn** then asks **Humes** about the fracture lines in the skull.

**Humes:** ...I didn't detail all those for the reasons that I stated in the protocol [the autopsy report]. They're going this way and they're going that way, and, you know, that's the way it goes (sic)...

**Gunn:** ...there are numbers written at the bottom, a 4, and a 3, over a 6. Do you see those?

**Humes:** Yeah.

**Gunn:** Do you know what those signify?

**Humes:** No.

**Gunn:** (p. 89): Was scalp missing?

**Humes:** There was some scalp missing, but we were able to pretty much close the scalp, skin, when we finished everything...

**Gunn:** So there was no scalp that came to the autopsy room?

*[Mantik note: The absence of such late arriving scalp is confirmation that Humes is probably right, that most of the scalp was there, although several centimeters may have been missing, as he soon recalls.]*

**Humes:** No.

**Gunn:** When the embalming process was completed, approximately how much scalp was missing?

**Humes:** Oh, I don't know. Maybe three or four centimeters, something 'like that. Not much...

*[Mantik note: Without seeming to be conscious of it, Humes is telling us quite directly that the photographs of the back of the head cannot be accurate. This is because they show the entire scalp present none at all is missing.]*

**Gunn:** Approximately where was the missing scalp as of the time that the embalming process was completed?

**Humes:** You got me (sic)...

**Gunn** moves on to the X-rays.

**Gunn** (p. 100): So all of the X-rays of the cranium were taken before ...any metal fragments were removed?

**Humes:** Exactly.

**Gunn:** Do you have any recollection now about the shapes of the fragments that were removed?

**Humes:** They were small and irregular. That's all I can tell you.

**Gunn:** Long and sliver like or roundish or any recollection?

**Humes:** Flat, irregular, two or three millimeters...

*[Mantik note: The suspicious object on the frontal X-ray is 6.5 mm and almost circular; it is hardly irregular.]*

**Gunn** (p. 107) then returns to the brain.

**Humes:** ...But the brain was damaged, and it didn't lend itself well to infusing it like we normally do. So we placed it in a very generous quantity of 10% formalin...

*[Mantik note: The elimination of perfusion, which Humes clearly implies here, means that the brain would gain rather little additional mass during the fixation process. Therefore, the argument of some that the large brain mass is due to fixation, becomes quite untenable.]*

**Gunn:** (p. 110): And the whole circumference of the entry wound was visible without any reconstruction of the skull?

**Humes:** Oh, yeah, sure.

*[Mantik note: No one else has ever said this, nor had Humes ever said this before! Such a central finding is conspicuously absent from the autopsy report, and from all other comments by each of the three pathologists. This conclusion is also not supported by the X-rays or by the prior reviews of any other specialist. Furthermore, such a circumferential hole, if present, surely ought to be visible somewhere in the photographic collection, but it is not. Despite Humes's apparent certainty about this question, his statement is categorically wrong. This comment by him is simply inexplicable.]*

**Gunn:** In which bone was the entrance wound?

**Humes:** Occipital bone...

**Gunn** then turns to the back wound.

**Gunn:** (p. 141): You see that Dr. Burkley identifies the posterior back [wound] at about the level of the third thoracic vertebra?

*[Mantik note: in the death certificate that he prepared as JFK's physician]*

**Humes:** Yes.

**Gunn:** Was that correct?

*[Mantik note: This is critical to the SBT; it should be much higher in order to sustain the SBT.]*

**Humes:** I don't know (sic). I didn't measure from which vertebra it was (sic). It's sometimes hard to decide which vertebra, to tell you the truth, by palpation. Maybe you can do it accurately because the first and second, did I say third? Oh, he says third thoracic. I think that's much lower than it actually was. I think it's much lower than it actually... you have seven cervical vertebrae. I don't know. I mean, he's got a right to say anything he wants, but I never saw it before, and I don't have an opinion about it (sic).

*[Mantik note: If it really was the first or second vertebra, Humes, by his own words here, has no excuse for not documenting this, since T1 and T2 can usually be identified without much difficulty. The HSCA chose T1. It probably was no higher than T1 or T2, but it may have been lower.]*

**Gunn:** Did you ever discuss which vertebra?

**Humes:** I never discussed anything about it with George Burkley, period, or anybody else. I mean, with all due respect, you seem to have come to me from left field (sic). You know, I just, they're not things which I'm aware of (sic)...

**Gunn** then asks about the date of the brain examination.

**Humes** (p. 146): I don't know, Monday or Tuesday [November 25 or 26] or some day at the beginning of the week.

**Gunn:** Earlier in the deposition today, you made reference to a sectioning of the brain. If I understood correctly, that took place one or two days afterwards.

**Humes:** Yeah.

*[Mantik note: This is an astonishing confession, since there are no photographs of such sections, even though Stringer recalls taking them. In fact, until this moment, the pathologists had officially insisted that the brain was not sectioned. In view of Douglas Home's proposal of two separate brain examinations (on two different dates with two different brains), it is quite certain that Humes is here recalling the one occasion at which the authentic brain actually was sectioned, but for which no official records remain.]*

**Gunn:** Did that happen within one or two days after?

**Humes:** Yes, shortly after. I can't tell you what day now.

*[Mantik note: There is no documentary evidence for this early date, but Humes is recalling the examination of JFK's brain on (probably) the morning of the funeral (Monday), whereas the substitute brain, described in the official report, was examined about a week later (possibly on another Monday). This chronology fits with all of the evidence; see Home's article for more on these issues. These apparent slips of memory by Humes actually provide further corroboration for Home's proposal.]*

*Gunn refuses to abandon this issue and he asks Humes again for the date.*

**Humes:** (p. 149): A couple of days after Sunday [November 24], after they were delivered. I don't know... In that week someday... I don't really know. It didn't seem to be important to me at the time, and still doesn't, quite candidly (sic).

*[Mantik note: Anyone who wanted to know where the brain went would take great exception to this eccentric, or possibly feigned lack of interest by Humes. If the brain had been buried with the body on Monday, November 25, then any examination after this could not be of JFK's brain, despite Humes's indifference. That such a misleading, later examination occurred is Douglas Horne's (highly probable) proposal.]*

**Gunn:** Did you ask [Admiral Burkley] or wonder how they would be able to inter the brain if the President had already been buried?

**Humes:** No, I didn't worry about it one way or another (sic)...

*In view of the great paradoxes about the back of the head photograph (Figure 1) Gunn next wants to know if the hair was cleaned before the photographs were taken.*

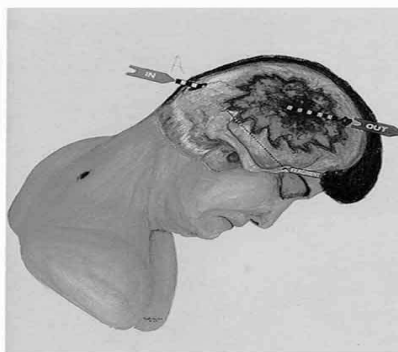
**Gunn:** (p. 156): No cleaning, no combing of the hair or anything or that sort?

**Humes:** No, no, no, no, no.

**Gunn** later returns to the question of whether any occipital bone was missing.

**Gunn:** (p. 171): So on the scalp of President Kennedy here, still in View No. 4 [see Figure 1], that underneath the scalp the bone was all intact with the exception of the puncture wound...

**Humes:** Yeah...



*Figure 5*

*[Mantik note: This is flagrantly at odds with the X-rays, and even with Humes's own diagram for the Warren Commission (Figure 5), and even with Humes's own autopsy report. Once again, Humes is behaving in a totally incomprehensible fashion.]*

*Gunn then turns to the "entry" wound on the posterior head photograph (Figure 1); he is inquiring about the red spot, high on the back of the head.*

**Gunn:** (p. 177): Dr. **Humes** are you able to identify what you have described previously as an entrance wound in the posterior skull of President Kennedy on photographs in View 6?

**Humes:** This is the same problem I had at the [HSCA] committee hearings. ...I had difficulty trying to see which was which among these things, between here and there (sic) ...I mean, they threw these up on a great big screen and said which is what, and I really had difficulty. I couldn't be sure. I 'm disappointed. I was disappointed in that regard. I still have trouble with it.

**Gunn:** Are you able to identify on View 6 the entrance wound?

**Humes:** Not with certainty, I'm sorry to tell you.

**Gunn** next refers to the small white spot just above the hairline (Figure 1) on the right rear of the skull. This is more than 10 cm below the red spot.

**Gunn:** (p. 180): ...is that where you now would identify what you believe to be the entrance wound in the skull?

**Humes:** I cannot flat-footedly say that. I have trouble with it. The head is turned toward one side I don't know. It's very difficult, very difficult. It's an educated guess, to be perfectly honest.

*[Mantik note: only slightly, not enough to matter].*

**Gunn:** For that marking that is towards the bottom near the hairline [the white spot], what is your best understanding of what that designates?

**Humes:** I don't have the foggiest idea (sic). See what's important is where is the wound in the bone. You can't tell from these pictures.

*[Mantik note: Humes is right, it is the bone that really matters; unfortunately for Humes, and for history, too, no unambiguous photographs of this bone exist. However, see my discussion in the Postscript, in which precisely such a photograph, from the current official set, is identified.]*

**Gunn:** (p. 181): Did you have any difficulty identifying the scalp entry wound during the time of the autopsy?

**Humes:** No, I didn't at the time of the autopsy...

*[Mantik note: This is one of the most damning statements of his testimony. He had already made the same statement to JAMA. No doubt, the three pathologists could identify the wound, both in the skull and in the scalp. However, the only obvious wound in the photographs (the red spot) was not seen by anyone at either Parkland or at Bethesda. The three pathologists (and the two photographers and the radiologist, too) certainly did not give any importance to the red spot, unequivocally denying that it represented an entry site. The only individuals to give any importance to it had not seen the body.]*

*Gunn next turns to my questions about the metal fragments. They begin by looking at the frontal X-ray.*

**Gunn:** (p. 183): Could you examine the B&W photographs and see if they help?

**Humes:** They don't help me. You can't even see any wound in the upper area of this (sic)...

*Gunn then turns to the mysterious skull photograph F8. See the Postscript, where, with the assistance of the X-rays, I demonstrate that this is the sole remaining photograph that does indeed show the authentic large hole at the right rear of the skull. Recall also that Robert*

*McClelland, after returning from the Archives, volunteered that the current collection does contain such a photograph. F8 is the one. Once this is granted, then such a large hole immediately implies a frontal headshot. It is hardly surprising, therefore, that additional photographs, which would have properly oriented this wound, have been deliberately lost.*

**Gunn:** (p. 185): The first question for you would be whether you can orient those photos so as to describe what is being represented in the photographs.

**Humes:** Boy, it's difficult. I can't. I just can't put them together. I can't tell you what...

**Gunn:** Can you identify whether that is even posterior or frontal or parietal?

**Humes:** No, I can't...

**Humes's** troubles don't stop there; he has the same problems with the brain photographs, as follows.

**Gunn** (p. 203): ...If you can just look at the basilar view [from underneath] of the brain, if you could describe what that view shows...

**Humes:** Boy, I have trouble with this. I don't know which end is up (sic). I don't know what happened here...

*[Mantik note: Having seen these at the Archives, I know that this is really not so difficult as Humes implies.]*

**Gunn** (p. 213): Did you notice that what at least appears to be a radio-opaque fragment during the autopsy [the mysterious 6.5 mm object]?

**Humes:** Well, I told you we ...retrieved one or two, and of course, you get distortion in the X-ray as far as size goes.

*[Mantik note: That is not true in this case; there is actually very little image magnification, as I have determined from detailed measurements on the X-rays at the Archives; Humes is merely buying time for his answer here.]*

**Humes:** The ones we retrieved I didn't think were of the same size as this would lead you to believe.

*[Mantik note: That is certainly true of those metal fragments now in the Archives, as I discovered when I examined them. The most striking finding is actually the discrepancy in shape (of these metal fragments in the Archives) when compared to the fragments seen in the X-rays: the larger one is not 7x2 mm, as seen above the right frontal sinus in the X-rays, but (in the Archives collection) it is rather pancake shaped. None of the tests performed on this object should have changed its shape. This paradoxical shape, by itself, is a bizarre situation and has never been examined or discussed by any official body.]*

**Gunn:** Did you think they were larger or smaller?

**Humes:** Smaller. Smaller, considerably smaller... But I don't remember retrieving anything of this size.

*[Mantik note: This confession was the best possible confirmation of my X-ray work. Humes has no memory of the 6.5 mm object, the same one that I concluded was actually not on the X-ray during the autopsy. The other two pathologists agreed, and the radiologist, when asked this question, abruptly terminated the entire conversation, which was never resumed. The entire purpose of the X-*

rays was to locate such metal objects. The invisibility of this object to the pathologists, and to all other autopsy observers, as well as its absence from the forensic record is surely one of the deepest mysteries of this entire case. I believe that this mystery has now been solved with the proposal of selectively (and critically) altered X-rays, i.e., the 6.5 mm object was superimposed on the original X-ray by a simple dark room technique which I have both discussed and demonstrated. In 1963, this was surprisingly easy to do; my prior essay (*Assassination Science*, 1998, pp. 120-137) even cites recipes from contemporaneous textbooks that could have been employed in precisely such an undertaking. I have been able, using current duplicating film, to produce astonishing figures, such as a scissors (made of air) lying entirely inside a skull, or a pterodactyl flying around inside a human skull. I have shown these actual composite X-rays (not just pictures of them) at public lectures. For an early description of my work, see Anthony and Robbyn Summers, "The Ghosts of November;" *Vanity Fair* (December 1994), p. 97.]

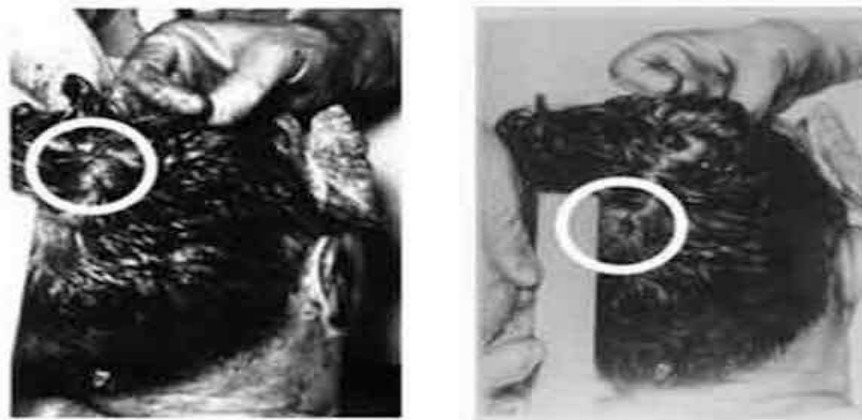
**Gunn:** Well, that was going to be a question, whether you had identified that as a possible fragment and then removed it?

**Humes:** Truthfully, I don't remember anything that size when I looked at these films. They all were more of the size of these others.

*[Notice that he does not claim a loss of memory about this object. He clearly implies that he does remember, and that it simply was not there.]*

**Gunn:** What we're referring to is a fragment that appears to be semicircular.

**Humes:** Yeah...



*Figure 1*

*Gunn then asks about the dark frontal area on the lateral skull X-ray (Figure 1 A-B), an area that appears to contain almost no tissue at all, despite that fact that the body and brain photographs suggest little or no missing tissue at this same site.*

**Humes** (p. 216): What seems to be the frontal portion of it. I don't understand why that is [so dark]. You'd have to have some radiologist tell me about that (sic). I can't make that out... I don't understand this great void there [the dark area at the front]. I don't know what that's all about.

**Gunn** (p. 218): I had another question for you about the lateral X-ray... And that is whether you can identify the particles that you made reference to before and where they appear in this photograph.

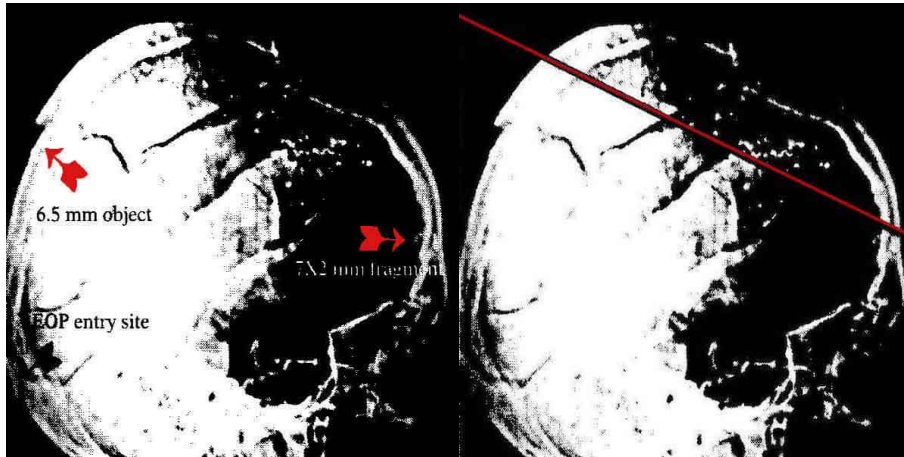


Figure 11A/B

*[Mantik note: He is asking about the trail of metallic debris (see 11A-B).]*

**Humes:** Well, you see, there's nothing in this projection [the lateral view] that appears to be of the size of the one that appeared to be above and behind the eye [the 6.5 mm object] on the other one [the frontal view]. But that could be positional or the other thing is an artifact (sic). I don't know what...

*[Mantik note: Actually the object at the rear of the lateral skull, that should correspond to the 6.5 mm object, is quite easy to see on the X-rays in the Archives. It was even described by Sibert and O'Neill in their FBI report. It spatially correlates with the 6.5 mm object on the frontal X-ray. It is the right size, almost exactly 6.5 mm high. These comments by Humes are simply inexplicable. I do not know whether he is being deliberately obtuse or whether he truly does not understand the X-rays.]*

**Gunn:** Do those metal fragments, or do those radio-opaque objects help you in any way identify entrance or exit wounds?

**Humes:** No. No, they really don't.

**Gunn:** Is there any relationship or correlation between those metal fragments and the bullet wound?

**Humes:** Not that I can make out at all, no. They seem to be random.

*[Mantik note: Most likely, they represent the trail of a frontal bullet, as is discussed elsewhere in my essay above.]*

**Gunn:** OK. Dr. Humes, I'd like to show you ...the autopsy [report], and ask if you would read the paragraph on page 4...

*[Mantik note: This is about the bone fragments that were received late in the autopsy from Dallas.]*

**Humes:** ...And then we got these [bone] fragments, at one margin of it there's something that seemed to match up with that fragment that was still in the skull. My memory's pretty good (sic). I said we had three. That's what we have, I guess. I described several metallic fragments along the line [on the lateral X-ray] ...joining the occipital wound with the right supraorbital ridge [above the right eye]



**Gunn** (p. 221): Could you point out for me [on the lateral X-ray] where the minute particles of metal in the bone are in relationship to the small occipital wound and the right supraorbital ridge?

**Humes**: Well, they don't relate at all in this picture, as far as I'm concerned.

**Gunn**: "This picture" being [the lateral X-ray]

**Humes**: Yeah. I don't know where I got that, but there's the occipital wound would never be up that high... There's nothing up there (sic)...

**Gunn** (p. 222): Do you see any fragments that correspond with a small occipital wound?

**Humes**: No.

*[Mantik note: I have confirmed this on the X-rays in the Archives; there is no metallic debris near the low occipital site that the pathologists identify as the entry site, although that does not necessarily disqualify it as an entry site.]*

**Gunn**: Do you recall having seen an X-ray previously that had fragments corresponding to a small occipital wound?

**Humes**: Well, I reported that I did, so I must have (sic). But I don't see it now (sic)... All I know is that I wrote it down. I didn't write it down out of whole cloth (sic). I wrote down what I saw.

*[Mantik note: No X-ray of JFK shows such a trail near the occipital entry site. This reply by Humes is preposterous. On one hand, he claims that the X-rays are authentic, but, on the other hand, he says that, in 1963, he actually saw a metallic trail extending from low on the skull, near his entry site, to the supraorbital area. This is sheer, unassailable nonsense, and Humes must surely know it. Gunn probably took this line of questioning as far as he could go. Any further questions, I am told by Douglas Horne, might have propelled Humes straight out of the room. Humes has been caught in the fundamental lie of the X-rays. For those who like smoking guns, this is as close as anything gets in this case.]*

**Gunn**: Does that raise any question in your mind about the authenticity of the X-ray that you're looking at now in terms of being an X-ray of President Kennedy?

**Humes**: Well, there are aspects of it I don't understand. I don't understand this big void up maybe a radiologist could explain it. I don't know what this big... [Dark area at the front of the lateral X-ray] that takes up half of the skull here I don't understand that.

**Gunn**: Do remember seeing that on the night of the autopsy?

**Humes**: No, I don't...

*[Mantik note: Nonetheless, he has still claimed that the X-rays are authentic.]*

*Gunn soon after wants to know whether Humes ever met President Johnson.*

**Humes** (p. 236): I met with President Johnson, but not in any way connected with this. In fact, I'm wearing a pair of cuff links that he gave me today. I was able to report to him that the nodule we took out of his larynx was benign, and he was very happy.

**Gunn:** I can imagine. I would be, too. You don't wish your cuff links to be part of the exhibit (sic)

**Humes:** Oh, I think we ought to just take that out of the report, if you don't mind. I shouldn't have mentioned it, I suppose. But not everybody has a pair of these presidential cuff links (sic).

*Before closing the deposition, Gunn asks the one question that should routinely be asked of all witnesses, but which, given the straitjacket donned by the legal set, was almost never asked by the Warren Commission or by the HSCA.*

**Gunn** (p. 236): ... [can you] think of any additional information that would ... help provide a better understanding of either what happened during the autopsy or the wounds that were inflicted on President Kennedy?

**Humes:** I have trouble conjuring up; I wish that the photographs were more graphic and more specifically helpful than they are. I'm 'disappointed by that, and I didn't find that out with certainty, really, until I got to that House Select Committee hearing. I had difficulty. There were a lot of people around, and they were showing and throwing these up, and I really didn't have the time that I had even today. I was even more confused at that point. But, you know, that's spilled milk...

**Gunn:** Are there any additional comments that you'd like to make? I told you I'd give you that opportunity.

**Humes:** No. I'm still somewhat vague on the precise bottom line of all your efforts to do these things. ...But if you ask a person enough questions often enough, you're going to confuse themselves sooner or later and not say the same thing twice ...so I'm concerned that we've got so much information put together that we, well, there's an expression in golf. You get paralysis of analysis. You know, you get more information than you can usefully put together. But that's for your, I mean, that's for you to decide, not me. I can't tell...

**Humes's** summary:

Besides reading the transcript, I have listened to the actual tape of this deposition (as well as many others listed here). What struck me (and what is not evident in the transcript) is how quickly, and how unhesitatingly, **Humes** affirmed the authenticity of both the X-rays and the photographs (of both the brain and the body). Yet he cannot identify several critical features in the posterior head photograph (such as his supposedly obvious entry wound that did not require any shaving of the head, as he stated to JAMA), nor can he orient either the brain photographs or the mystery F8 photograph of the skull, nor does he understand (or even recall) the large dark area at the front of the lateral skull X-ray, nor can he (even remotely) explain why the trail of bullet debris disagrees by four inches with his official report, nor can he explain why the most important object on the extant X-rays, the largest "metal" fragment was neither seen nor removed during the autopsy. After all of this (apparent) ineptitude, and despite forthrightly (and often) admitting confusion and uncertainty during his interrogation, he nonetheless insists that there is one point about which he is still certain, the photographs and the X-rays are authentic. As the deposition with **Humes** closed, he avowed that he would rather not undergo such questioning every day.

As I pondered this, I could not but think of Lyndon Johnson's first address to Congress (27 November 1963):

"All I have I would have given gladly not to be standing here today."

*[Editor's note: If the official government account is correct, then why has so much of the evidence in this case been altered, created, or destroyed? The simplest explanation for government involvement in the cover-up, after all, is government involvement in the crime. Indeed, when systematically applied to alternative theories, government involvement is the only hypothesis that can adequately explain what we now know about the death of JFK.]*

*Article from The New York Times (1 August 1998, p. A9)*

**SECOND SET OF PHOTOS OF KENNEDY AUTOPSY**

*WASHINGTON, July 31 (AP) –*

*According to testimony released today about the autopsy on President John F. Kennedy, a second set of photographs, in addition to the set at the National Archives, was taken of Kennedy's wounds. The second set of photographs was never made public and its whereabouts is not known. The second set is 'believed to have been taken by a White House photographer, Robert L Knudsen, during or after the autopsy, at the National Naval Medical Center in Bethesda, Md. Its existence raises new questions about how the autopsy was conducted, a subject of Intense debate for 35 years.*

[The Warren Commission and The Warren Report] both ignored or suppressed what was opposed to the predetermined conclusion that Oswald alone was the assassin.

*This meant that the destruction, alteration and manipulation of evidence had to be "overlooked."*

***It was.***

*This meant that impossible testimony from preposterous witnesses had to be credited.*

***It was.***

*This meant that invalid reconstructions had to be made.*

***They were.***

*This meant that valuable evidence available to the Commission had to be avoided.*

***It was.***

This meant that the incontrovertible proofs in the photographs had to be replaced by elaborate and invalid re-enactments which, in turn, had to be based upon inaccuracies, misinformation and misrepresentation, which is what was done.

-Harold Weis